

Successful vital pulp therapy in a child two years since untreated complicated crown fracture: a case report with twenty-four month follow-up

Author: Dr Amanda M. Leske

Author affiliation: Bendigo Health Community Dental Services, Victoria, Australia

Author corresponding address: Bendigo Health Community Dental Services, 100 Barnard Street,

Bendigo, VICTORIA, AUSTRALIA 3550

Author corresponding email: amandamleske@gmail.com

Successful vital pulp therapy in a child two years since untreated complicated crown fracture: a case report with twenty-four-month follow-up

Abstract

Complicated crown fractures account for a significant proportion of injuries to young permanent teeth in children. The success of vital pulp therapy after significant delay in treatment of dental trauma is not often reported. This case report describes successful partial pulpotomy of an upper central incisor with traumatic complicated crown fracture in a nine-year old girl, where the initial injury remained untreated for two years due to her significant dental anxiety and inability to access appropriate care. The patient is followed for twenty-four months after vital pulp therapy, affirming the ongoing success of the treatment. This case confirms that vital pulp therapy should remain the treatment of choice for complicated crown fractures, in the absence of any definitive signs or symptoms of necrotic pulp, even despite significant delays between injury and treatment. This treatment option can bestow multiple positive benefits for children including reduced burden of treatment and lessened risk of root fracture while promoting ongoing development of young permanent teeth.

Introduction:

Trauma to permanent incisors is a common event, affecting around one quarter of children.¹ Complicated crown fracture is defined as a tooth fracture involving loss of enamel and dentine with exposure of the pulp and represents a significant proportion (up to 20%) of traumatic injuries in children.^{1,2} In most circumstances, vital pulp therapy is recommended as the treatment of choice after complicated crown fracture.² The extent to which treatment delay affects prognosis of such treatment is still largely unknown, and few case reports exist which document successful outcomes after delays longer than a few weeks.^{3,4} This case report describes the unexpected occurrence of successful vital pulp therapy in a nine-year-old girl after a treatment delay of two years since traumatic complicated crown fracture of upper central incisor, and follows the case for twenty-four months to confirm ongoing success.

Case description:

A healthy nine-year-old female was referred from her general dentist in April 2018 for management of injured teeth 11 and 21 (Figure 1). The patient complained of spontaneous, lingering and nocturnal aching pain from tooth 11, with non-lingering sensitivity to cold stimulus from tooth 21. According to the patient's family and reports from previous dentists, the patient had sustained dental trauma to teeth 11 and 21 while holidaying abroad in mid-2016 (Figure 1). Their overseas dentist was unable to provide dental treatment due to lack of patient cooperation, and it was not until the family emigrated to Australia over a year later that they again sought treatment for the injury from their local general dentist. The patient was subsequently referred for specialist paediatric dental care due to lack of patient cooperation preventing any dental treatment for her injuries.

On clinical examination in June 2018, the extra-oral findings were unremarkable. The intra-oral examination (Figure 2/A, 2/B) revealed the mixed dentition was present and multiple carious lesions, hypomineralised enamel, unsatisfactory restorations and abscessed lower left primary molars were noted. Teeth 11 and 21 exhibited mesio-incisal oblique complicated crown fractures with no evidence of prior restoration. The pulp of tooth 21 was visible as a red/brown hue (Figure 2/A). Orthodontic examination revealed Class 2 Division 1 incisor relationship with deep overbite and limited restorative space for fractured teeth 11 and 21 due to supraeruption of lower incisors over the long period between injury and treatment. Tooth 11 had no response to carbon dioxide (CO₂) and was tender to percussion (TTP); 21 displayed an immediate and non-lingering response to CO₂ and was not TTP. No mobility or other clinical pathology were noted.

Periapical radiograph of tooth 21 (Figure 2/C) was taken on initial presentation. Teeth 11 and 21 displayed complicated crown fractures, 11 had periapical radiolucency but 21 peri-radicular area appeared normal. An orthopantomogram (OPG) taken in April 2018 (Figure 2/D) demonstrated multiple other dental pathologies. A comprehensive treatment plan to manage the patient's entire dentition was devised, with

input from specialist orthodontist and oral and maxillofacial surgeon, and informed consent from the family.

Considering there were signs of a vital pulp, it was decided to attempt vital pulp therapy on tooth 21. The patient was treated in the chair for management of teeth 11 and 21 with non-pharmacological behaviour management. Local anaesthesia was achieved using 2.2mL lignocaine 2% (1:80,000 adrenaline) via infiltration and teeth 11 and 21 were isolated with rubber dam. Under copious water spray, approximately 4mm of pulp tissue was removed from tooth 21 with a high-speed sterile diamond bur until fresh pink bleeding pulp was reached. Haemostasis was achieved with pressure from damp sterile cotton pellets within five minutes. Non-setting calcium hydroxide was placed over the pulpal surface (Pulpdent Paste®, Pulpdent), covered by a layer of setting calcium hydroxide (Dycal, Dentsply Sirona) and then a light-cured glass ionomer cement liner (Vitrebond™, 3M™). Gingivectomy was performed around teeth 11 and 21 using an electrosurgery unit (PERFECT TCS II 240 Volt, Coltene Whaledent) to expose the mesio-palatal fractured margins to allow restoration with direct resin composite (Filtek™ Z250 Universal Restorative, 3M™). Conventional endodontic treatment was completed on tooth 11 over two appointments using thermoplastic gutta percha. To allow restorative space and improve longevity of restorations, an upper removable orthodontic appliance with anterior bite plane was then utilised to correct overbite over a four-month period. Teeth 11 and 21 were then restored with direct composite resin crowns (Filtek™ Z250 Universal Restorative, 3M™ USA). Multiple other preventive, restorative and surgical dental treatments were performed to manage dental caries, enamel hypomineralisation and ectopic teeth and the patient was reviewed three-monthly for twenty-four months.

Periapical radiographs at twelve (Figure 3/B) and twenty-four-month (Figure 4/B) reviews demonstrated narrowing of pulp chamber and dentine bridge formation in tooth 21 with no obvious peri-radicular pathology. Satisfactory endodontic treatment and healing of 11 peri-apical radiolucency was also noted, with no new dental pathology. Over the twenty-four-month follow-up since treatment, tooth 21 had displayed no signs or symptoms of pathology and maintained a positive response to CO₂, indicating signs

of a vital pulp. The patient will continue to attend for ongoing reviews according to her caries and trauma risk.

Discussion:

Management options for complicated crown fractures in permanent teeth include direct pulp capping, superficial Cvek pulpotomy (partial pulpotomy), deep partial/coronal pulpotomy (cervical pulpotomy), pulp extirpation or, rarely, extraction.² Guidelines from the International Association of Dental Traumatology² advise that vital pulp therapy is management of choice for complicated crown fractures, with partial pulpotomy demonstrating favourable outcomes in the current literature.⁴ Calcium hydroxide was selected as the partial pulpotomy medicament in this case due its good success rates and ready availability in the immediate public dental setting.⁵

Due to factors such as tooth sensitivity, infection risk and aesthetic concerns, complicated crown fractures of anterior teeth should be treated as soon as possible.² However, the extent to which treatment delay affects prognosis is still largely unknown.⁶ In theory, the more time elapsed, the greater propensity for bacterial invasion and less chance for pulpal healing.^{7,8} Animal and human studies have reported numerical trends correlating decreased success of partial pulpotomy and delayed treatment; however, many suffer from inadequate sample sizes.⁹

On the other hand, numerous studies have demonstrated that partial pulpotomy is a viable option after complicated crown fracture, even despite treatment delays.^{4,6-8} Cvek⁸ reported a 96.7% success rate of partial pulpotomy in 60 children's teeth, with no significant differences found between those teeth who had treatment within one hour or up to 90 days after trauma. However, most children in this study received treatment within five days of injury and the two teeth that demonstrated unfavourable healing were ones that received delayed treatment, 17-30 hours after trauma.⁸ Wang, Wang and Qin⁴ found the time interval (0.5 hours-4 months) between complicated crown fracture and treatment did not significantly affect the pulp survival rate after partial or cervical pulpotomy. Only one other known case report documents successful vital pulp therapy after a delay as long as in this particular case, although the

case reported by Caliskan and Savranoglu³ included a tooth with combination complicated crown fracture and horizontal root fracture, which may have contributed to ensuring ongoing blood supply to the coronal pulp.³

It is remarkable that in the case at hand, vital pulp therapy was successful for a tooth with complicated crown fracture which remained open and untreated for two years. As defined in the literature, the criteria for success after vital pulp therapy includes lack of clinical and radiographic signs of necrosis, continued apexogenesis, radiographic dentine barrier and response to sensibility testing; all of which were observed in this case.² Cvek⁸ advocated that most failures of vital pulp therapy could be observed within the first year after treatment, and that the presence of a continuous dentine bridge was a significant sign of success. Reasons for ongoing vitality of tooth 21 in this case may be related to the rich vascularity and cellularity of the pulp tissue in a young child which might produce defences to resist bacterial contamination and retain ability to repair after injury.³ Gingival overgrowth was also noted into the site of the pulp exposure which may have afforded protection through bathing of gingival crevicular fluid.¹⁰

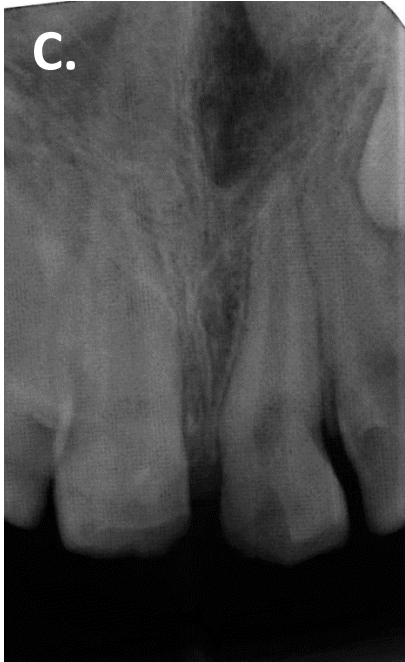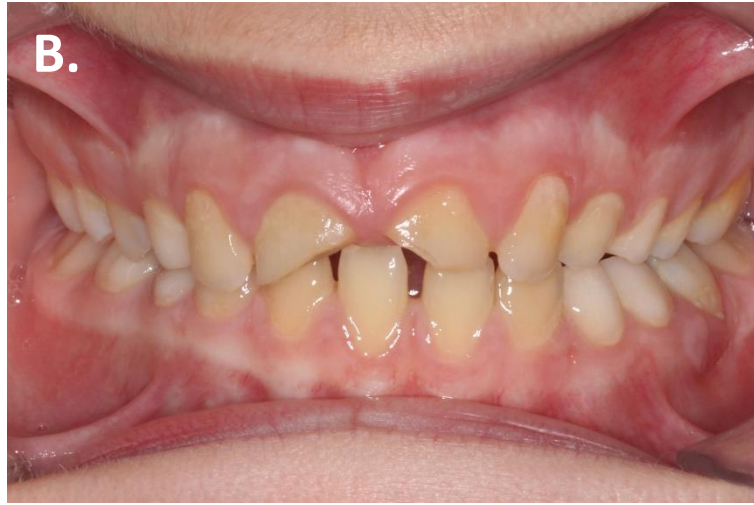Conclusion and clinical implications:

This is an interesting case in that a permanent incisor with a complicated crown fracture maintained its vitality over a two-year period without treatment, and vital pulp therapy appears to have been ultimately successful. This case demonstrates that vital pulp therapy should remain the treatment of choice for complicated crown fractures, in the absence of any definitive signs or symptoms of necrotic pulp, even despite significant delays between injury and treatment. This treatment option can bestow multiple positive benefits for children including reduced burden of treatment and lessened risk of root fracture while promoting ongoing development of young permanent teeth.

Figures

Oral Medicine – Mucosal Orthodontics Prosthodontics - Fixed	Oral Medicine – Facial Pain & TMJ Paediatric Dentistry Prosthodontics – Removable	Oral Medicine – Allergies Periodontics Special Needs
Details for the referral:		
11,21- both pulp exposed, after trauma in 2016 in Jordan/ 11 PAR: present, 21 large pulpal exposure/ pulp bleeding/ pt in not cooperative in dental chair/ pa showed apices closed 11,21.		
Patient's / Person Responsible's main concern / dental needs (in their own words)		
bleeding tooth 21 on and off		
Briefly describe how the service requested fits in your overall treatment plan.		
please assist in management of 11,21 - rct indicated.		
Summary of medical history: (please ensure a current copy is in the patient's record)		
NRMH		

Figure 1. Initial referral of patient from general dentist indicating dental trauma sustained two years prior to presentation and limited cooperation of patient

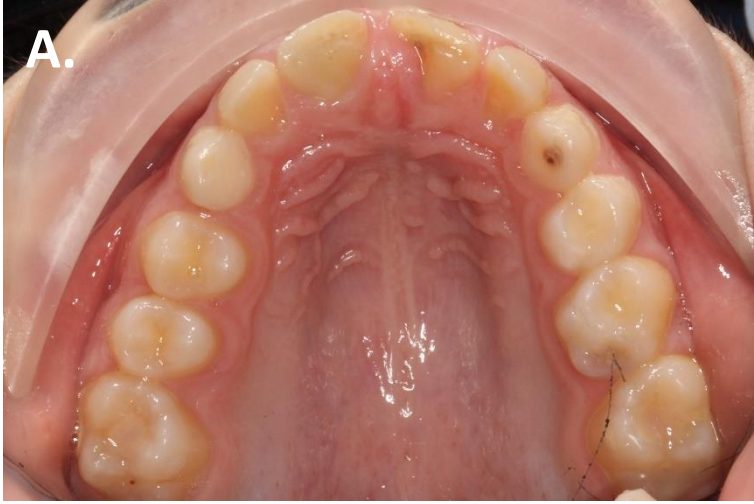

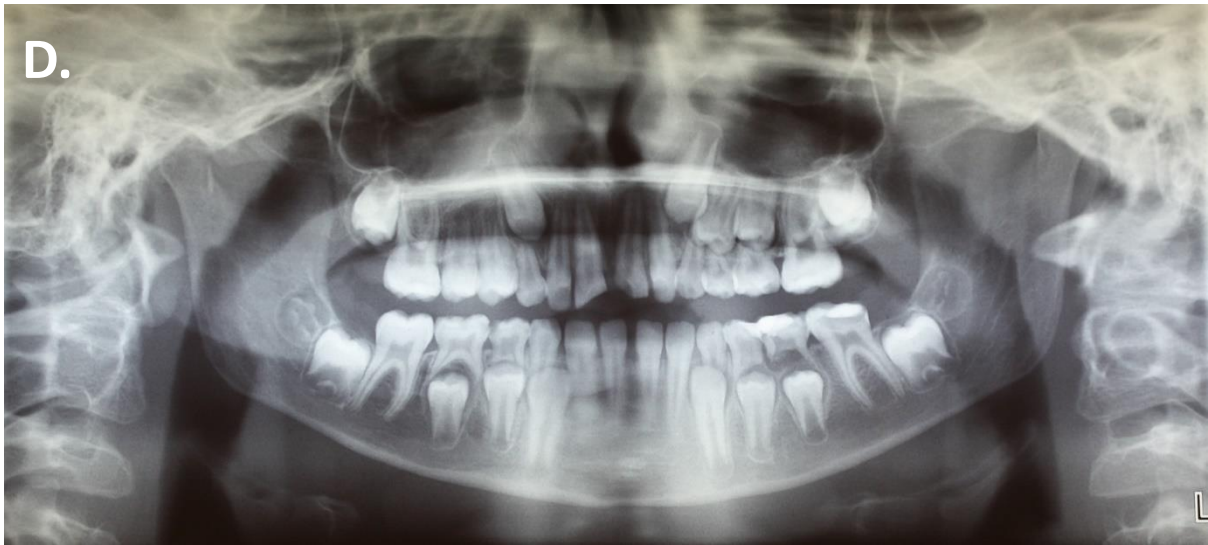


Figure 2. Clinical photographs and radiographs taken on initial presentation including (A) maxillary occlusal view clinical photograph, (B) frontal view clinical photograph, (C) periapical radiograph centred on tooth 21 and (D) orthopantomogram (taken two months prior to presentation). Red/brown hue of exposed pulp of tooth 21 is visible with gingival overgrowth into exposure site, as is supraeruption of lower incisors into restorative space.

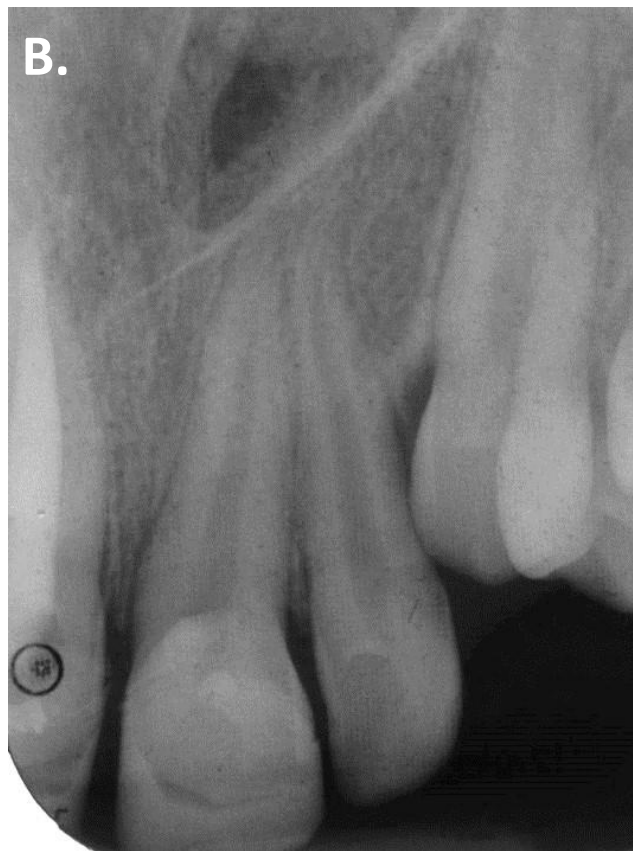
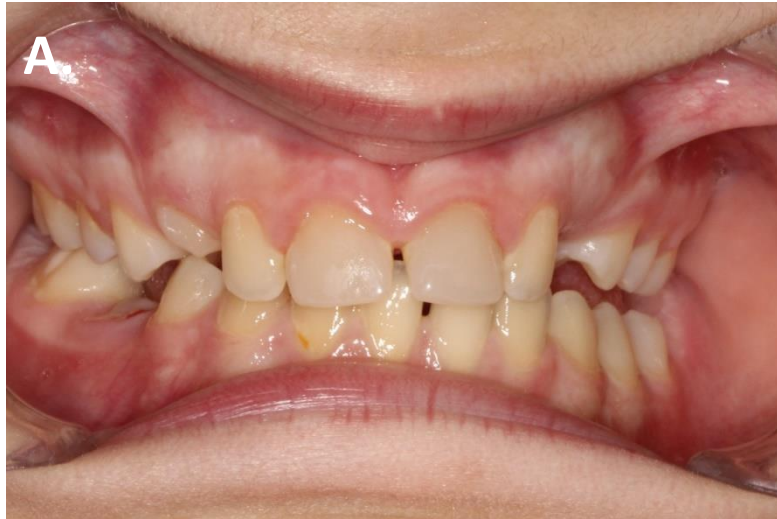
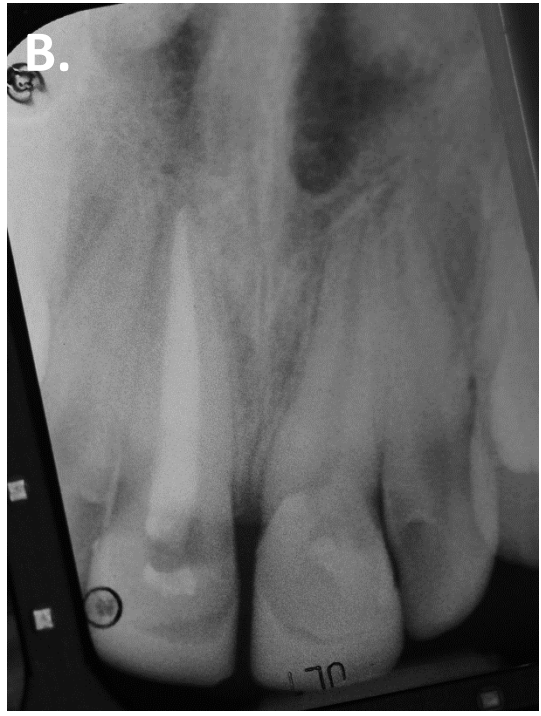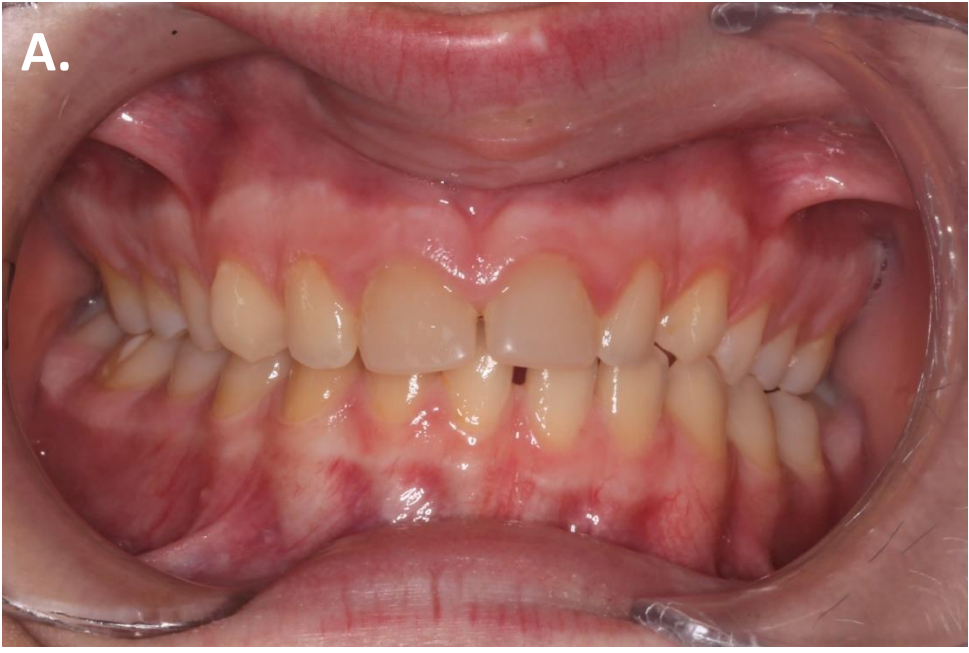Figure 3. (A) Clinical and (B) radiological presentation of tooth 21 at one year review since treatment showing apparent dentinal bridge between pulpotomy site and pulp canal, narrowing of pulp canal and no obvious periapical pathology.



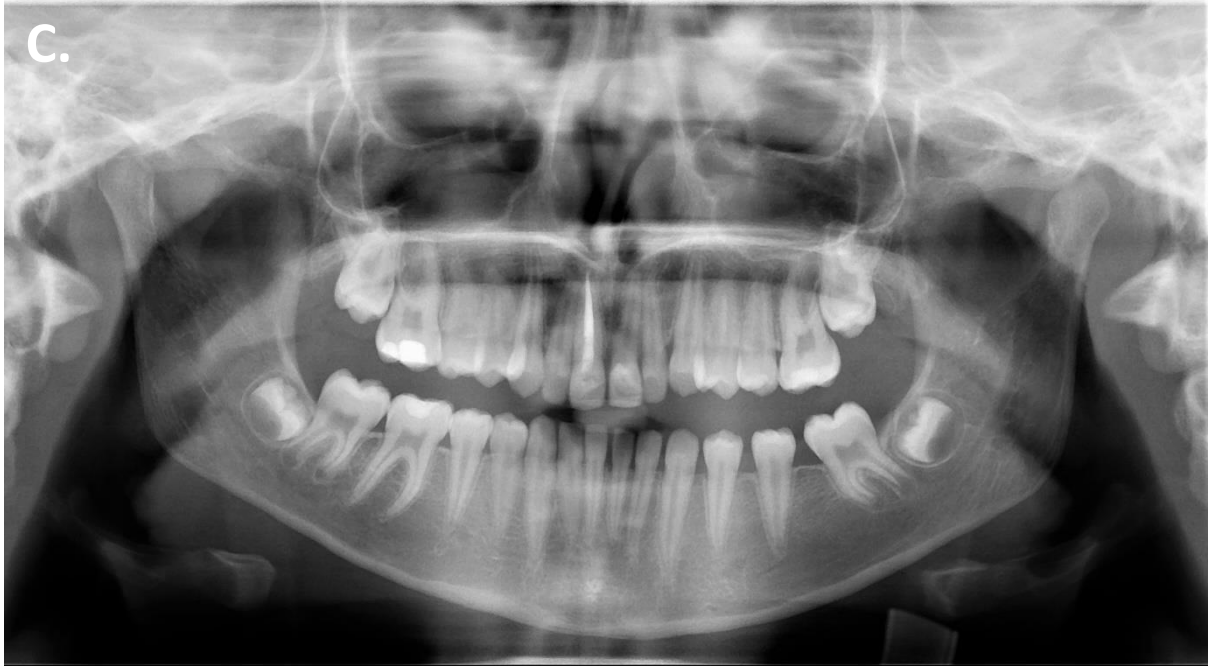

Figure 4. (A) Clinical photograph, (B) periapical radiograph and (C) orthopantomogram at two-year review since treatment. Tooth 21 is showing apparent dentinal bridge between pulpotomy site and pulp canal with ongoing narrowing of pulp canal and no obvious periapical pathology.

References

1. Glendor U. Epidemiology of traumatic dental injuries - a 12 year review of the literature.(report). *Dental Traumatology* 2008;24: 603-11.
2. Bourguignon C, Cohenca N, Lauridsen E, Therese Flores M, O'Connell A, Day P, et al. International association of dental traumatology guidelines for the management of traumatic dental injuries: 1. Fractures and luxations. *Dental Traumatology* 2020;00: 1-5.
3. Caliskan MK, Savranoglu S. Delayed partial pulpotomy in a midroot and complicated crown-root-fractured permanent incisor with hyperplastic pulpitis: A case report. *J Endod* 2010;36: 1250-3.
4. Wang G, Wang C, Qin M. Pulp prognosis following conservative pulp treatment in teeth with complicated crown fractures - a retrospective study. *Dental Traumatology* 2017;33: 255-60.
5. Chen Y, Chen X, Zhang Y, Zhou F, Deng J, Zou J, et al. Materials for pulpotomy in immature permanent teeth: A systematic review and meta-analysis. *BMC Oral Health* 2019;19: 227-36.
6. Bimstein E, Rotstein, I. Cvek pulpotomy - revisited. *Dental Traumatology* 2016;32: 438-42.
7. Andreasen JO, Andreasen FM, Skeie A, Hjorting-Hansen E, Schwartz O. Effect of treatment delay upon pulp and periodontal healing of traumatic dental injuries -- a review article. *Dent Traumatol* 2002;18: 116-28.
8. Cvek M. A clinical report on partial pulpotomy and capping with calcium hydroxide in permanent incisors with complicated crown fracture. *J Endod* 1978;4: 232-7.
9. Cvek M. Partial pulpotomy in crown-fractured incisors-results 3-15 years after trauma. *Acta Stomatol Croat* 1993;27: 167-73.
10. Caliřkan MK, Oztop F, Caliřkan G. Histological evaluation of teeth with hyperplastic pulpitis caused by trauma or caries: Case reports. *Int Endod J* 2003;36: 64-70.